



A histopathological study of the effects of ezetimibe and atorvastatin combination against gentamicin-induced kidney injury

Ali Hasanpour Dehkordi¹, Banafsheh Yalameha², Aiyoub Pezeshgi^{3*}, Hamid Nasri⁴, Elham Bijad⁵

¹Social Determinants of Health, Research Center, School of Allied Medical Sciences, Shahrekord University of Medical Sciences, Shahrekord, Iran

²Nickan Research Institute, Isfahan, Iran

³Department of Internal Medicine and Zanjan Metabolic Disease Research Center, School of Medicine, Zanjan University of Medical Sciences, Zanjan, Iran

⁴Department of Internal Medicine, Isfahan University of Medical Sciences, Isfahan, Iran

⁵Medical Plants Research Center, Basic Health Sciences Institute, Shahrekord University of Medical Sciences, Shahrekord, Iran

ARTICLE INFO

Article Type:
Original

Article History:

Received: 20 November 2020

Accepted: 14 February 2021

Published online: 28 February 2021

Keywords:

Gentamicin
Kidney injury
Ezetimibe
Atorvastatin

ABSTRACT

Introduction: Co-administration of ezetimibe (EZT) and atorvastatin (AT) has been suggested as a new therapeutic strategy for some kinds of kidney injury.

Objectives: This experimental study was designed to evaluate the effects of AT and EZT combination against gentamicin (GM)-induced kidney injury in rats.

Materials and Methods: Twenty male Wistar rats were randomly assigned into five equal groups and treated as follows; group 1 (control group), group 2 (GM group, daily 80 mg/kg, i.p for 7 days), group 3 (GM 80 +AT 5+ EZT 2.5 mg/kg), group 4 (GM 80 +AT 25+ EZT 12.5 mg/kg) and group 5 (GM 80 +AT 75+EZT 37.5 mg/kg). Kidney sections were examined for histopathological parameters including vacuolization of tubular renal cells, degeneration, necrosis, tubular cell flattening and debris in tubular lumen.

Results: Compared to the control group, GM significantly exacerbated histopathological parameters. Treatment with AT and EZT combination in different doses could significantly decrement levels of vacuolization, necrosis and debris in nephrotoxic rats. Nevertheless, degeneration level was significantly reduced by only dose of AT 75+EZT 37.5.

Conclusion: The findings of this research indicated that AT+EZT therapy at different doses can ameliorate renal histopathological injury following GM injection.

Implication for health policy/practice/research/medical education:

The present study investigated the effects of ezetimibe plus atorvastatin against gentamicin-induced kidney injury in an animal model. The findings indicated that ezetimibe plus atorvastatin therapy at different doses can ameliorate renal histopathological injury following gentamicin toxicity.

Please cite this paper as: Hasanpour Dehkordi A, Yalameha B, Pezeshgi A, Nasri H, Bijad E. A histopathological study of the effects of ezetimibe and atorvastatin combination against gentamicin-induced kidney injury. J Nephropharmacol. 2022;11(x):e01.

DOI: xxxx.

Introduction

Gentamicin (GM), an aminoglycoside antibiotic, is widely applied for confronting gram-negative bacterial infections due to appropriate antibacterial influence and low cost. However, its clinical usage has been confined because of the presence of side effects such as nephrotoxicity (1). Functionally, GM is able to increment blood urea nitrogen (BUN), serum creatinine (Cr) (2) and decline glomerular filtration rate (GFR) (3). In addition to the content mentioned, GM promotes the production of superoxide

anion, hydroxyl radical, and hydrogen peroxide during oxidative stress by mitochondria of renal cells. Therefore, to prevent the damage of oxygen free radicals and reduce the GM-induced nephrotoxicity, diverse antioxidants have been exploited (4). One group of antioxidants of interest is statin, which might alleviate the deleterious effects of GM (5). Atorvastatin (AT) is an intrahepatic cholesterol level lowering drug, which belongs to statins. Statins act via inhibiting a rate-limiting enzyme of cholesterol biosynthesis pathway in the liver called 3-hydroxy-3-

methylglutaryl-coenzyme A (HMG-CoA) reductase. The drug enhances liver low-density lipoprotein (LDL) receptors expression and LDL uptake from the blood (6,7). Multiple studies have indicated that AT through its anti-inflammatory and immunomodulatory characteristics deter the progression of kidney disorders (8,9). Statins also neutralize glomerular injury induced by oxidized-LDL in human podocytes. In animal models, AT can induce nitric oxide accessibility and impede renal histologic failure (10). Additionally, AT possesses potent potential in the improvement of renal function markers (BUN as well as serum Cr) and renal morphology, and amplification of antioxidant capability in renal injuries (11, 12). Another drug used in dyslipidemia is called ezetimibe (EZT). EZT is recognized as a modern cholesterol absorption inhibitor drug that barred the absorption of biliary and dietary cholesterol without influence on triglycerides or fat-soluble vitamins (13,14). Recently, some studies have offered that co-administered EZT and statins may have more efficiency on hyperlipidemia and renal injuries including chronic kidney disease (CKD) (15). For instance, AT and EZT combination has been indicated as an appropriate option for hyperlipidemia treatment compared to high dose statin in rats (16). Furthermore, the EZT potency to diminish LDL is 10–18%, while in combination with statins lowers LDL by 25% (17). Therefore, it seems that the combination of EZT and AT has different effects on renal injuries.

Objectives

The present study evaluated the effects of AT and EZT combination against GM-induced kidney injury in rats.

Materials and Methods

Animals and study design

Twenty male Wistar rats with a mean body weight of 200–250 g in the Medical Plants Research Center in Shahrekord University of Medical Sciences were used for this study. The animals were kept at a controlled environment (temperature; 21–25°C and light cycle; 12 h dark–12 h light). Additionally, the rats were permitted free access to pelleted diet and tap water. Rats were randomly assigned into five equal groups and treated as follows:

Group 1, as the control group, received no drug. Group 2 received GM, 80 mg/kg daily for 7 days. All rats in groups 3, 4, and 5, first received GM (80 mg/kg) and after a 1-hour interval, the combination of AT (at doses of 5, 25, and 75 mg/kg, respectively) and EZT (at doses of 2.5, 12.5, and 37.5 mg/kg, respectively) was injected daily for 7 days.

Histopathological examination

At the end of the experiment, the animals' kidneys were dissected out and fixed in buffered formalin for 12 hours and processed for histopathological examinations. Three micrometer-thick paraffin sections were stained with hematoxylin and eosin (H&E). All specimens were

examined for histopathological parameters including vacuolization of tubular renal cells, degeneration, necrosis, tubular cell flattening and debris in tubular lumen.

Ethical issues

This study was performed according to the regulations of the Research Ethics Committee of Iranian Ethical Guidelines for the use of animals in research. Additionally, all animal experiments were in accordance with protocols approved by the United States National Institutes of Health (NIH, 1978). This study was also approved and supported by Ethics Committee of NIMAD (National Institute for Medical Research Development; <http://nimad.ac.ir/ethical> in Iran) (Ethical code#IR.NIMAD.REC.1399.024, Grant# 972048).

Statistical analysis

All data were expressed as the mean \pm standard error (SE). Differences between the groups were assessed with one-way ANOVA followed by post hoc Tukey's test using GraphPad Prism version 4.03. $P < 0.05$ was assumed to be statistically significant.

Results

Considerable differences were found in histopathological parameters including vacuolization, degeneration, necrosis, flattening and debris between groups ($P < 0.001$) (Figures 1A-E). Additionally, the results of Tukey's post-hoc test revealed that injection of GM significantly exacerbated vacuolization ($P < 0.001$), degeneration ($P < 0.001$), necrosis ($P < 0.001$), flattening ($P < 0.001$), and debris ($P < 0.01$) in the rats, compared to the control group.

There were substantial differences in vacuolization ($P < 0.001$ and $P < 0.01$), flattening ($P < 0.05$) and degeneration ($P < 0.05$ and $P < 0.01$) between groups 3 and 4 compared to the control group.

Additionally, treatment with AT and EZT combination in different doses (AT 5+EZT 2.5, AT 25+EZT 12.5, AT 75+EZT 37.5) could significantly decrement levels of vacuolization ($P < 0.01$ and $P < 0.001$), flattening (in order of dose, $P < 0.05$, $P < 0.01$ and $P < 0.001$), necrosis ($P < 0.001$) and debris ($P < 0.05$) in nephrotoxic rats. Nevertheless, degeneration level was significantly reduced by only dose of AT 75+EZT 37.5 ($P < 0.05$).

Discussion

It has been illustrated that patients with CKD suffer a secondary type of intricate dyslipidemia, as a major cause of cardiovascular disease (CVD) (18). Actually, dyslipidemia contributes to the advancement of CKD. Epidemiological reports have conveyed that CKD occurrence may be related to elevated serum total cholesterol and decreased high-density lipoprotein (HDL). Therefore, the utilization of hypocholesterolemic drugs including EZT and statins can be useful in ameliorating cholesterol levels

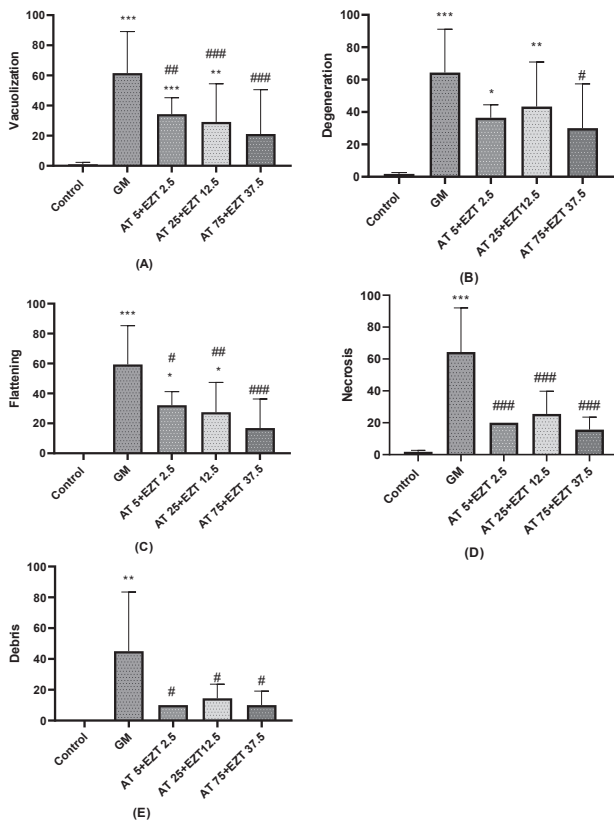


Figure 1. The effects of EZT and AT combination on histopathological parameters, including vacuolization (A), degeneration (B), flattening (C), necrosis (D) and debris (E) in GM-induced kidney injury. * $P < 0.05$ versus the control group, ** $P < 0.01$ versus the control group, *** $P < 0.001$ versus the control group, # $P < 0.05$ versus GM group, ### $P < 0.01$ versus GM group, #### $P < 0.001$ versus GM group. GM: gentamicin, AT: atorvastatin, EZT: ezetimibe.

and inhibiting renal dysfunction through their unique properties (19-21).

In this study, we investigated the effects of AZ and EZT combination against renal histopathological alterations following GM injection in an animal model. The findings indicated that administration of GM induces histopathological alterations in the rats' kidneys in agreement with other studies (22,23). In the present study, treatment of nephrotoxic rats with different doses of AT+EZT could improve the severity of renal impairment. Levels of vacuolization, flattening, necrosis and debris decreased significantly with three doses of AT+EZT compared to GM group, while in terms of degeneration, only a considerable difference was observed between AT 75+EZT 37.5 group and GM group. In this regard, numerous publications demonstrated more efficiency of statins with EZT in the improvement of CVD in patients with CKD (24, 25). For instance, it has been exhibited that the 10 mg of EZT+ different doses of statin has a severe effect on decreased LDL cholesterol levels by affecting pathways of cholesterol absorption and synthesis. In addition, 10 mg of EZT+20 mg of simvastatin diminished atherosclerotic

incidents in patients with CKD. Co-administration of EZT and statins was suggested as a new therapeutic agent for further prevention of hypercholesterolemia and CVD (26, 27). Recently, Singh et al with the evaluation of AT versus EZT on diabetic nephropathy reported that circulating cholesterol and renal fibrosis attenuated via both AT and EZT. However, the effect of AT in reducing renal injury was more than EZT (28).

GM poisonous on the kidney is via several mechanisms consisting of stimulation of apoptosis, necrosis, increase in endothelin-1 (ET-1) and transforming growth factor- β (TGF- β), elevated monocyte/macrophages penetration and oxidative stress (29). Multiple studies on animals demonstrated beneficial effects of statins against nephrotoxicity following drugs such as GM via different mechanisms containing improvement of oxidative stress status, deterrence of drug accumulation in the tubular cells, antithrombotic and anti-inflammatory effects (30-32). Additionally, EZT has been shown nephroprotective activity through its antioxidant properties (33,34). Thus, it seems that AT+EZT therapy is lucrative in reducing the severity of nephropathologic complications due to GM administration.

Conclusion

To sum up, the findings of this research indicated that the treatment with EZT plus AT at different doses can ameliorate renal histopathological injury following GM injection. However, the present study could not clearly show the effective doses of the drugs. Considering the prooxidant action of antioxidants in some situations, such as high doses (35), we recommend that further research should be undertaken to determine the effective doses and action mechanism of EZT and AT against GM-induced kidney injury.

Authors' contribution

Primary idea by: AP; Proposal preparing: HN; Animal lab supervision and headlining: AHD; Statistical analysis: EB; Primary draft by: AP and HN; Finalization of the study: AP and HN. All authors read and signed the final paper.

Conflicts of interest

The authors declare no conflict of interest.

Ethical considerations

Ethical issues (including plagiarism, data fabrication, double publication) have been completely observed by the authors.

Funding/Support

This research project was conducted by a grant from national institute for medical research development (NIMAD) (<http://nimad.ac.ir>) from Iran (Grant#972048 , ethical code #IR.NIMAD.REC.1399.024).

References

- Reiter RJ, Tan DX, Sainz RM, Mayo JC, Lopez-Burillo S. Melatonin: reducing the toxicity and increasing the efficacy of drugs. *J Pharm Pharmacol*. 2002;54:1299-321. doi: 10.1211/002235702760345374.
- Burns J, Yokota T, Ashihara H, Lean ME, Crozier A. Plant foods and herbal sources of resveratrol. *J Agric Food Chem*. 2002;50:3337-40.
- Romero F, Pérez M, Chávez M, Parra G, Durante P. Effect of uric acid on gentamicin-induced nephrotoxicity in rats—role of matrix metalloproteinases 2 and 9. *Basic Clin Pharmacol Toxicol*. 2009;105:416-24. doi: 10.1111/j.1742-7843.2009.00466.x.
- Shishehbor MH, Brennan ML, Aviles RJ, Fu X, Penn MS, Sprecher DL, et al. Statins promote potent systemic antioxidant effects through specific inflammatory pathways. *Circulation*. 2003;108:426-31. doi: 10.1161/01.CIR.0000080895.05158.8B.
- Ozbek E, Cekmen M, Ilbey YO, Simsek A, Polat EC, Somay A. Atorvastatin prevents gentamicin-induced renal damage in rats through the inhibition of p38-MAPK and NF-κB pathways. *Ren Fail*. 2009;31:382-92.
- Sirtori CR. The pharmacology of statins. *Pharmacol Res*. 2014;88:3-11. doi: 10.1080/08860220902835863.
- Stancu C, Sima A. Statins: mechanism of action and effects. *J Cell Mol Med*. 2001;5:378-87.
- Fuentes-Orozco C, García-Salazar SJ, Gómez-Navarro B, González-Espinoza E, Zepeda-González A, Ramírez-Robles JN, et al. Anti-inflammatory effect of atorvastatin on the kidney graft of living donor transplants. *Ann Transplant*. 2018; 23:442-449. doi: 10.12659/AOT.908521.
- Guillén D, Cofán F, Ros E, Millán O, Cofán M, Brunet M. Biomarker assessment of the immunomodulator effect of atorvastatin in stable renal transplant recipients and hypercholesterolemic patients. *Mol Diagn Ther*. 2010;14:357-66.
- Campese VM, Park J. HMG-CoA reductase inhibitors and the kidney. *Kidney Int*. 2007;71:1215-22.
- Zhou S, Zhao P, Li Y, Deng T, Tian L, Li H. Renoprotective effect of atorvastatin on STZ-diabetic rats through attenuating kidney-associated dysmetabolism. *Eur J Pharmacol*. 2014;740:9-14. doi: 10.1016/j.ejphar.2014.06.055.
- Jaikumkao K, Pongchaidecha A, Chattipakorn N, Chatsudhipong V, Promsan S, Arjinajarn P, et al. Atorvastatin improves renal organic anion transporter 3 and renal function in gentamicin-induced nephrotoxicity in rats. *Exp Physiol*. 2016;101:743-53. doi: 10.1113/EP085571.
- Van Heek M, Farley C, Compton DS, Hoos L, Alton KB, Sybertz EJ, et al. Comparison of the activity and disposition of the novel cholesterol absorption inhibitor, SCH58235, and its glucuronide, SCH60663. *Br J Pharmacol*. 2000;129:1748-54. doi: 10.1038/sj.bjp.0703235.
- Knopp R, Bays H, Manion C, Lipka L, Melani L, LeBeaut A, et al. Effect of ezetimibe on serum concentrations of lipid-soluble vitamins. *Atheroscler Suppl*. 2001;2:90.
- Kerzner B, Corbelli J, Sharp S, Lipka LJ, Melani L, LeBeaut A, et al. Efficacy and safety of ezetimibe coadministered with lovastatin in primary hypercholesterolemia. *Am J Cardiol*. 2003;91:418-24.
- Prasad A, Datta PP, Roy R, Pattanayak C, Panda P. Comparative study of ezetimibe and atorvastatin alone and in combination on lipid profile in rats. *Mater Sociomed*. 2013;25:192-95. doi: 10.5455/msm.2013.25.192-195.
- Vavlukis M, Vavlukis A. Adding ezetimibe to statin therapy: latest evidence and clinical implications. *Drugs Context*. 2018;7:212534. doi: 10.7573/dic.212534.
- Lennernäs H. Clinical pharmacokinetics of atorvastatin. *Clin Pharmacokinet*. 2003;42:1141-60.
- Ishimitsu T, Ohno E, Ueno Y, Onoda S, Nagase A, Ohira T, et al. Effects of atorvastatin and ezetimibe on endothelial function in dyslipidemic patients with chronic kidney disease. *Clin Exp Nephrol*. 2014;18:704-10. doi: 10.1007/s10157-013-0904-7.
- Schaeffner ES, Kurth T, Curhan GC, Glynn RJ, Rexrode KM, Baigent C, et al. Cholesterol and the risk of renal dysfunction in apparently healthy men. *J Am Soc Nephrol*. 2003;14:2084-91.
- Mänttari M, Tiula E, Alikoski T, Manninen V. Effects of hypertension and dyslipidemia on the decline in renal function. *Hypertension*. 1995;26:670-5.
- Edeogu CO, Kalu ME, Famurewa AC, Asogwa NT, Onyeji GN, Ikpeko KO. Nephroprotective effect of Moringa oleifera seed oil on gentamicin-induced nephrotoxicity in rats: biochemical evaluation of antioxidant, anti-inflammatory, and antiapoptotic pathways. *J Am Coll Nutr*. 2020;39:307-15. doi: 10.1080/07315724.2019.1649218.
- Medić B, Stojanović M, Rovčanin B, Kekić D, Škodrić SR, Jovanović GB, et al. Pioglitazone attenuates kidney injury in an experimental model of gentamicin-induced nephrotoxicity in rats. *Sci Rep*. 2019;9:13689. doi: 10.1038/s41598-019-49835-1.
- Sweeney ME, Johnson RR. Ezetimibe: an update on the mechanism of action, pharmacokinetics and recent clinical trials. *Expert Opin Drug Metab Toxicol*. 2007;3:441-50. doi: 10.1517/17425255.3.3.441.
- Bae J, Hong N, Lee BW, Kang ES, Cha BS, Lee YH. Comparison of renal effects of ezetimibe–statin combination versus statin monotherapy: a propensity-score-matched analysis. *J Clin Med*. 2020;9:798. doi: 10.3390/jcm9030798.
- Gagné C, Bays HE, Weiss SR, Mata P, Quinto K, Melino M, et al. Efficacy and safety of ezetimibe added to ongoing statin therapy for treatment of patients with primary hypercholesterolemia. *Am J Cardiol*. 2002;90:1084-91.
- Naderi S, Foody JM. Ezetimibe and simvastatin for the prevention of cardiovascular events in predialysis chronic kidney disease patients: a review. *Int J Nephrol Renovasc Dis*. 2012;5:165-69. doi: 10.2147/IJNRD.S28159.
- Singh RS, Chaudhary DK, Mohan A, Kumar P, Chaturvedi CP, Ecelbarger CM, et al. Greater efficacy of atorvastatin versus a non-statin lipid-lowering agent against renal injury: potential role as a histone deacetylase inhibitor. *Scientific reports*. 2016;6:38034. doi: 10.1038/srep38034.
- Balakumar P, Rohilla A, Thangathirupathi A. Gentamicin-induced nephrotoxicity: do we have a promising therapeutic approach to blunt it? *Pharmacol Res*. 2010;62:179-86. doi: 10.1016/j.phrs.2010.04.004.
- Somay A. Atorvastatin prevents gentamicin-induced renal damage in rats through the inhibition of p38-MAPK and NF-κB pathway. *Ren Fail*. 2009; 31:382-392.

31. Chen HH, Chen TW, Lin H. Pravastatin attenuates carboplatin-induced nephrotoxicity in rodents via peroxisome proliferator-activated receptor α -regulated heme-oxygenase-1. *Mol Pharmacol.* 2010;78:36-45. doi: 10.1124/mol.109.061101.
32. Antoine DJ, Srivastava A, Pirmohamed M, Park BK. Statins inhibit aminoglycoside accumulation and cytotoxicity to renal proximal tubule cells. *Biochem Pharmacol.* 2010;79:647-54. doi: 10.1016/j.bcp.2009.09.021.
33. Nakamura T, Sato E, Fujiwara N, Kawagoe Y, Ueda Y, Suzuki T, et al. Ezetimibe decreases serum levels of asymmetric dimethylarginine (ADMA) and ameliorates renal injury in non-diabetic chronic kidney disease patients in a cholesterol-independent manner. *Pharmacol Res.* 2009;60:525-8.
34. Phan BAP, Dayspring TD, Toth PP. Ezetimibe therapy: mechanism of action and clinical update. *Vasc Health Risk Manag.* 2012;8:415-27. doi: 10.2147/VHRM.S33664.
35. Jamshidi-Kia F, Wibowo JP, Elachouri M, Masumi R, Salehi Jouneghani A, Abolhassanzadeh Z, et al. Battle between plants as antioxidants with free radicals in human body. *J Herbmed Pharmacol.* 2020;9:191-199. doi: 10.34172/jhp.2020.25.

Copyright © 2022 The Author(s); Published by Society of Diabetic Nephropathy Prevention. This is an open-access article distributed under the terms of the Creative Commons Attribution License (<http://creativecommons.org/licenses/by/4.0>), which permits unrestricted use, distribution, and reproduction in any medium, provided the original work is properly cited.