



The role of ^{99m}Tc dimercaptosuccinic acid scintigraphy in detection of vesicoureteral reflux in pediatrics with first episode of acute pyelonephritis

Mohsen Akhavan Sepahi^{1,2}, Mohammad Reza Razavi^{1,2}, Mojtaba Sabahi Fakher², Zahra Movahedi^{2,3*}

¹Department of Pediatric Nephrology, Qom University of Medical Sciences and Health Services, Qom, Iran

²Pediatric Clinical Research of Development Center, Hazrat Masoomeh Hospital, Qom University of Medical Sciences and Health Services, Qom, Iran

³Department of Pediatric Infectious disease, School of Medicine, Qom University of Medical Sciences and Health Services, Qom, Iran

ARTICLE INFO

Article Type:
Original

Article History:
Received: 3 March 2018
Accepted: 14 May 2019
Published online: 31 May 2019

Keywords:
Acute pyelonephritis,
Urinary tract infection Tc-
^{99m} DMSA scan, Voiding
cystourethrogram

ABSTRACT

Introduction: Acute pyelonephritis is a common disease in children leading to permanent renal function impairment due to renal scarring with the risk of later hypertension.

Objectives: The aim of this study was to assess the role of initial ^{99m}Tc dimercaptosuccinic acid (DMSA) scintigraphy for detecting the early renal parenchymal damage in children with the first episode of acute pyelonephritis (APN).

Patients and Methods: This study was conducted among 161 hospitalized children with the first clinically episode of APN from January 2008 to April 2013 in pediatric clinical research of development center in Qom, Iran. DMSA renal scintigraphy, ultrasonography (US), erythrocyte sedimentation rate (ESR), urine analysis and culture were performed in all patients. DMSA renal scan and voiding cystourethrogram (VCUG) was done within 15 days and one month after the diagnosis of APN using the standard protocol, respectively.

Results: Children with the first episode of acute pyelonephritis aged 1 month to 12 years were enrolled in this study. There were no statistically significant correlations between initial decreased uptake detected by DMSA renal scan with age, gender, body temperature, CRP levels or ESR. The positive and negative predictive values (PPV, NPV) of diminished uptake on DMSA renal scans for detecting the presence of VUR on VCUG were (43.2%) and (93.3%), respectively.

Conclusion: Children with a normal DMSA renal scan during their the first episode of UTI rarely have VUR. Avoidance of VCUG in children with negative DMSA renal scans could significantly eliminate the use of this potentially traumatic test.

Implication for health policy/practice/research/medical education:

DMSA (^{99m}Tc dimercaptosuccinic acid) renal scintigraphy should be considered as a gold standard method for evaluating the pediatric urinary tract infection. Therefore voiding cystourethrogram should be recommended only in patients with abnormal DMSA scan.

Please cite this paper as: Akhavan Sepahi M, Razavi MR, Sabahi Fakher M, Movahedi Z. The role of ^{99m}Tc dimercaptosuccinic acid scintigraphy in detection of vesicoureteral reflux in pediatrics with first episode of acute pyelonephritis. J Nephroarmacol. 2019;8(2):e27. DOI: 10.15171/npj.2019.27

Introduction

Acute pyelonephritis is a common disease in children leading to permanent renal function impairment due to renal scarring with the risk of later hypertension. Sometimes diagnosis of urinary tract infection (UTI) is difficult because the clinical and laboratory findings are nonspecific. According to the previous meta-analysis, the incidence of renal scarring following acute pyelonephritis (APN) was from 26.5% (Australia) to 49.0% (Asia) (1).

There are several risk factors for renal scar in children

after UTI including age, gender, recurrent infection, degree of fever, treatment delay and presence of vesicoureteral reflux (VUR). In addition, uropathogenic bacteria, host defense factors and genetic susceptibility are considered as other probable factors. The effect of inflammatory mediators on scar formation has been studied previously (2).

The diagnosis of APN is conducted by clinical and laboratory findings. Before 2006, voiding cystourethrogram (VCUG) was recommended by pediatric societies for all

*Corresponding author: Zahra Movahedi, Email: movahedizahra7@gmail.com

children with the first episode of UTI (3), but according to 2007 guideline published by the National Institute of Health and Clinical Excellence, invasive procedure for detecting VUR was obviated (4). Accordance to 2011 American Academy of Pediatrics (AAP) guideline, VCUg is not necessary for all children with the first episode of UTI (5).

Technetium 99 dimercaptosuccinic acid (DMSA) is considered as the current gold standard for the detection of renal parenchymal involvement (6). DMSA renal scintigraphy is the most sensitive and reliable method for detecting APN and renal scars in pediatric population (7-9). Specificity of this method for detecting the APN is 100 % (8). Therefore, DMSA should be considered to manage the first episode of childhood febrile UTI, rather than sonography or VCUg (10,11). Sensitivity of DMSA scan for differentiation between APN and cystitis is about 90%, using DMSA scintigraphy (12). Normal DMSA has high negative predictive value for rule out the high degrees of VUR (grades 3 to 5). On the other hand, when the initial DMSA is normal, the occurrence of renal scar is rare (12). In patients with symptomatic UTI, VCUg should be considered to determine the presence of VUR. There are controversial issues about the treatment of renal abnormalities which are detected by VCUg (13). Because the identification of VUR in patients with negative DMSA finding is rare, performing VCUg has been proposed only in patients with abnormal DMSA (13).

Objectives

We carried out a prospective study of 161 Iranian children referred to pediatric medicine research center with first clinically episode of APN for assessing the relationship between DMSA findings with clinical, laboratory and sonographic findings and to find the role of DMSA scan for early diagnosis of APN.

Patients and Methods

Study population

This prospective study was conducted among 161 hospitalized Iranian infants and children (31 boys and 130 girls) aged 1 month to 12 years (mean age: 35.37 months) with a first clinically suspected episode of APN. The study was carried out in pediatric medicine research center from January 2008 to April 2013.

Tc-99m DMSA renal scintigraphy, ultrasonography (US), erythrocyte sedimentation rate (ESR), C-reactive protein (CRP), white blood cell count (WBC), urine analysis and culture and VCUg were conducted for all patients.

Inclusion criteria

Evidence of APN included high fever ($>38.5^{\circ}\text{C}$), dysuria, abdominal pain, vomiting, and ≥ 10 leukocytes/mL in high power field (HPF) examination of urine and positive urine culture.

Exclusion criteria

Previous history of UTI, concurrent urogenital abnormality or uropathy except VUR were considered as exclusion criteria.

All patients received a standardized clinical examination including abdominal and lumbar palpation, temperature and blood pressure measurement. Laboratory tests including complete blood count, ESR, CRP were performed for all patients. All children with proven UTI underwent ultrasonography. DMSA renal scan and VCUg was done within 15 days and one month after the diagnosis of APN using a standard protocol, respectively (14,15). APN was diagnosed by high fever ($\geq 38.5^{\circ}\text{C}$), ESR ≥ 20 mm/h, CRP ≥ 10 mg/L, WBC $\geq 15000/\text{mm}^3$, pyuria ≥ 10 cell/HPF of urine and positive urine culture (16). Culture of $\geq 10^5$ colony-forming units/ml of a single urinary tract pathogen in midstream urine or 5×10^4 colony in urine obtained by catheter, since more than one colony of gram negative bacteria in suprapubic urine sample were considered as positive culture. Sonographic data including decreased or increased cortical echogenicity or reduced cortico-medullary differentiation with or without focal or diffuse renal enlargement, irregularity of renal outlines and decreased in parenchymal mass were considered as APN findings. Abnormal DMSA scan was determined by the presence of renal scars, focal or diffuse areas with decreased radionuclide uptake or thinning the renal cortex. On DMSA scan, APN was defined by the presence of focal or diffuse areas with decreased uptake of radionuclide or diffusely reduced uptake in an enlarged kidney.

Renal scarring was determined by the presence of decreased radionuclide uptake (17-19).

Ethical issues

Human rights were respected in accordance with the Helsinki Declaration 1975, as revised in 1983. The study protocol was approved by the research ethics committee of pediatric medicine research center of Qom University of Medical Sciences and Health Services (Ref #D/24/185). This paper is part of M.D, thesis of Mojtaba Sabahi Fakhri (#93-01-01-8260), in conducted in department of nephrology of this university.

Statistical analysis

The descriptive statics were expressed as mean \pm SD. The statistical analysis was performed using SPSS 16.0. Accordingly paired t test, was applied to assess of variants. P value ≤ 0.05 was considered significant.

Results

A total of 161 Iranian infants and children, 19.7 % boys ($n=31$) and 81.3 % girls ($n=130$), were enrolled in this study. Their median age was 36.37 months with age distribution one month to 12 years. DMSA scintigraphy showed changes consistent with APN in 86.3 % ($n=139$)

of patients. The sensitivity and specificity DMSA scan for diagnosing of UTI was 86% and 91% respectively, but it cannot differentiate between the injury by UTI and congenital kidney damage. While we had excluded the patients with underline kidney disease and also the patients with history of previous UTI, we considered all cases of abnormal DMSA as APN.

Frequency of clinical and laboratory finding of patients is shown in Table 1.

Since, many cases but not all patients with APN have fever, however in patients without fever, the diagnosis of APN was conducted by other clinical presentation and positive urinary culture. Relationship between the findings of DMSA scan and gender, age, fever, urinary symptoms, ESR and CRP level, ultra-sonographic finding, presence and VUR grading are indicated in Table 2.

There was no significant relationship between fever, urinary symptoms, ESR and CRP level and severity of DMSA abnormality, whereas DMSA findings were significantly higher in females and also in patients with VUR. Relation of abnormal DMSA finding and VUR was presented in Figure 1.

Renal ultrasonography

Abnormal renal ultrasound results were seen in 20 (12.4%) children. In all patient within this group, DMSA results were abnormal since VUR was detected in their VCUG.

DMSA scintigraphy

DMSA scans were performed during 7 to 14 days after admission (median of 10 days). Abnormal DMSA scan results were found in 139 (86.3%) children. Among them, 117 (72.7%) were shown mild abnormality. In 42(26%)

Table 1. Frequency of clinical and laboratory finding in patients

	Frequency	Percent
Fever	96	59.6
Urinary symptoms	85	52.8
Hematuria	50	31.1
Pyuria	129	80.1
High CRP	68	42.2
High ESR	90	55.9
Positive urine culture	109	67.7
APN sonographic changes	20	12.4
APN DMSA Finding	139	86.3
VUR	64	39.8
Grade 1	0	0
Grade 2	7	4.3
Grade 3	41	25.5
Grade 4	8	5
Grade 5	8	5

Abbreviations: CRP, C-reactive protein; ESR, erythrocyte sedimentation rate; APN, acute pyelonephritis; DMSA, dimercaptosuccinic acid; VUR, vesicoureteral reflux.

patients with mild DMSA abnormality, VUR were detected while only one patient with normal scan had VUR.

Within 52 children with negative urine culture and clinical and laboratory evidence of UTI, the DMSA scan showed parenchymal involvement in 84.6% of them (n=44).

Vesicoureteral reflux

VCUG was performed in all patient after obtaining a negative urine culture, since VUR was presented in 64 children (39.8%). High grade of VUR (grades 3 to 5) was diagnosed in 57 cases (35.5%). Forty-one patients had VUR grade 3. Eight children showed VUR grade 5, and 8 of them were presented in grade 4.

Discussion

The aim of this study was to determine the role of DMSA scan in early diagnosis of APN and detection of VUR by comparing the results of DMSA and VCUG. We also sought to determine the correlation between clinical, laboratory and ultra-sonographic data with DMSA finding.

In our study 19.3% and 80.7% of patients with first APN were male and female respectively.

According to other studies results, positive DMSA finding in girls was significantly more than boys (19,20). In this study, evidence of APN was detected in 86.3% of

Table 2. Relationship between DMSA finding and clinical and laboratory data

	DMSA abnormality		P value	
	Positive	Negative		
Male	21 (67.7%)	10 (32.3%)	< 0.05	
Female	118 (90.8%)	12 (9.2%)		
High fever	83 (86.5%)	13 (13.5%)	0.956	
Urinary symptoms	78 (91.8%)	7 (8.2%)	0.034	
Hematuria	43 (86%)	7 (14%)	0.934	
Pyuria	113 (87.6%)	16 (12.4%)	0.349	
Leukocytosis	38 (86.4%)	6 (13.6%)	0.995	
Positive CRP	57 (83.8%)	11 (16.2%)	0.428	
High ESR	81 (90%)	9 (10%)	0.127	
Positive urine culture	95 (86.3%)	44 (31.7%)	0.661	
<i>Escherichia coli</i>	65 (82.3%)	14 (17.7%)	0.542	
<i>Klebsiella spp.</i>	12 (100%)	0		
<i>Staphylococcus aureus</i>	2 (100%)	0		
<i>Proteus spp.</i>	6 (100%)	0		
<i>Pseudomonas aeruginosa</i>	5 (100%)	0		
<i>Citrobacter spp.</i>	3 (100%)	0		
Others	2 (100%)	0		
APN sonographic finding	20 (100%)	0		0.057
VUR	63 (98.4%)	1 (1.6%)		0.0001
Grade 1	76 (78.4%)	21 (21.6%)		0.0006
Grade 2	6 (85.7%)	1 (14.3%)		
Grade 3	41 (100%)	0		
Grade 4	8 (100%)	0		
Grade 5	8 (100%)	0		

Abbreviations: CRP, C-reactive protein; ESR, erythrocyte sedimentation rate; APN, acute pyelonephritis; DMSA, dimercaptosuccinic acid; VUR, vesicoureteral reflux.

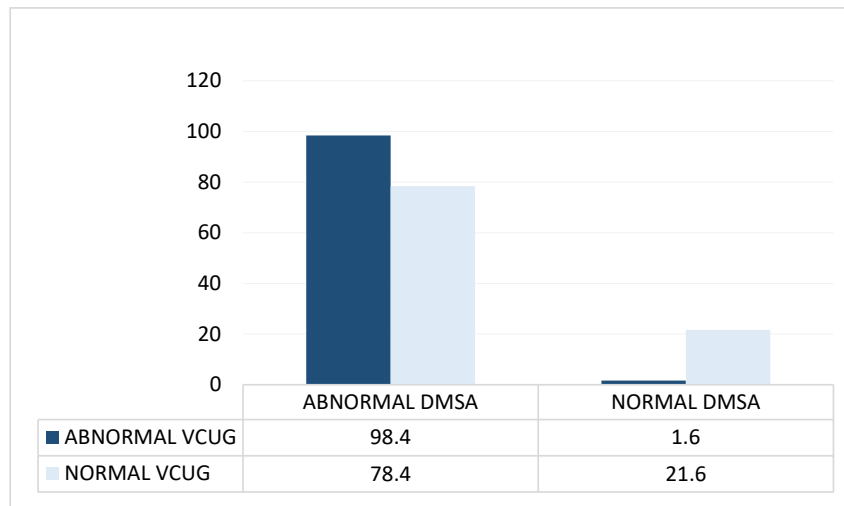


Figure 1. Relationship between abnormal DMSA finding and VUR.

patients on DMSA finding that was similar to the rate of earlier reports (12,19). VUR was found in 39.8% of children with first UTI.

Although one patient had VUR despite normal DMSA scan, the VUR was graded as mild. It means that in the presence of normal DMSA, probability of high grade VUR is low. If we regard a small number of patient with low grade VUR (grades 1 and 2), VCUG could be omitted in the presence of normal DMSA, which is potentially traumatic.

We found, parallel to increased reflux grading, abnormal DMSA finding was increased significantly. Therefore, children with high grade of VUR (more than grade 3) will get benefit from antimicrobial prophylaxis, because previous report showed in the presence of high grade VUR (grades 3 and more), the risk of APN will be high (21), however using antimicrobial agents in VUR grades 1 or 2 is challenging (22-24). Regarding the study by Friedman et al, presence of UTI with non *E. coli* agents was associated with higher reflux grading; however in our study, this correlation was not found (25).

According to the Jodal and Rosenberg, most patients with abnormal DMSA scan had VUR. According to the study by Abdelhalim et al, top-down approach can strict the VCUG numbering (26) but Wongbencharat et al detected performing VCUG, 6 months after infection, has more sensitivity for diagnosis of high grade VUR (9). Shaikh et al demonstrated both ultrasonography and DMSA do not have enough accuracy for detection of VUR (27). Correlation between CRP, ESR, leukocytosis, fever and urinary finding such as hematuria and pyuria was not compatible with previous studies (28,29). Sixty-eight percent of patients had positive urine culture, without any significant correlation between fever and positive urine culture. In fact in some UTI episodes, fever was not detected. Previous studies showed negative urine culture

could not rule out the UTI (30), due to increased urine output, high fluid intake, and slow growth uropathogens such as *Staphylococcus saprophyticus* which make low-count bacteriuria in the absence of previous antibiotic using (31).

In this study, 84.6% of patients with negative urine culture had positive DMSA findings and there was no correlation between positive urine culture and urinary tract imaging data including sonography or DMSA scan. On the other hand, the rate of positive data scan in patients with positive and negative urine culture was equal, because the patients with APN could have negative DMSA finding. Normal ultra-sonographic findings were detected in 87.6% of cases, whereas 89.4% of these patients had abnormal DMSA scan. Abnormal ultrasonic results demonstrating APN were found in 12.4% (n=20) of patients with defective DMSA, while there was any positive sonographic abnormality in APN with normal scan. According to previous studies, sonography cannot be a sensitive method for the diagnosing of APN (32,33), while ultrasound study could be helpful for detecting anatomical evaluation. Sorkhi et al showed low grade VUR cannot be predicted by ultrasonography or DMSA scan or by both of them (34). We found in the presence of negative urine culture, DMSA scintigraphy can help the physician to determine whether the VCUG is necessary or not. In the absence of decreased uptake in DMSA, detecting the VUR in VCUG is not probable. We recommend VCUG should be considered when results of DMSA show decreased uptake.

Conclusion

Lack of adequate characteristic data in neonatal and pediatric UTI has resulted in some difficulty in differentiation of lower and upper UTI. Renal ultrasonography, DMSA and VCUG findings have

important roles in the diagnosis of APN. There is no significant correlation between gender, duration of fever before antibiotic administration, leukocytosis, elevated ESR, and high levels of CRP with severity of renal damage. DMSA scan should be considered as a gold standard method for evaluating the pediatric UTI. Therefore VCUG should be recommended only in patients with abnormal DMSA scan. However, further investigation will be necessary for using a DMSA scan as the primary imaging study in the first episode of pediatric UTI.

Limitations of the study

The small proportion of patients included in this study was one the limitations of this research.

Authors' contribution

MAS; Study design, data collection. ZM; Study design, manuscript written and manuscript submission. MSF; Data collection. MRR; study design. All authors read and signed the final version of the manuscript.

Conflicts of interest

All authors have declared that no conflict of interest exists.

Ethical considerations

Ethical issues (including plagiarism, data fabrication, double publication) have been completely observed by the authors.

Funding/Support

This paper is part of the thesis of Mojtaba Sabahi Fakher No 93-01-01-8260, in Department of Nephrology, Qom University of Medical Sciences and Health Services.

References

1. Faust WC, Diaz M, Pohl HG. Incidence of post-pyelonephritic renal scarring: a meta-analysis of the dimercapto-succinic acid literature. *J Urol* 2009; 181: 290-7. doi:10.1016/j.juro.2008.09.039.
2. Sharifian M, Shiva MR, Akhavan Sepahi M, Shohadaee S, Esfandiari N, Fallah F. Urinary Ghrelin Concentration in Children With Urinary Tract Infections Before and After Treatment. *Arch Pediatr Infect Dis*. 2016;4: e34096. doi: 10.5812/pedinfect.34096.
3. Park YS. Renal scar formation after urinary tract infection in children. *Korean J Pediatr*. 2012;55:367-70. doi: 10.3345/kjp.2012.55.10.367.
4. Soltanifar S, Russell R. The National Institute for Health and Clinical Excellence (NICE) guidelines for caesarean section, 2011 update: implications for the anaesthetist. *Int J Obstet Anesth*. 2012;21:264-72. doi: 10.1016/j.ijoa.2012.03.004.
5. Newman TB. The new American Academy of Pediatrics urinary tract infection guideline. *Pediatrics*. 2011;128: 572-5. doi: 10.1542/peds.2011-1818.
6. Shaikh N, Ewing AL, Bhatnagar S, Hoberman A. Risk of renal scarring in children with a first urinary tract infection: a systematic review. *Pediatrics*. 2010;126:1084-91. doi: 10.1542/peds.2010-0685.
7. Yoo JM, Koh JS, Han CH, Lee SL, Ha US, Kang SH, et al. Diagnosing Acute Pyelonephritis with CT, Tc-DMSA SPECT, and Doppler Ultrasound: A Comparative Study. *Korean J Urol*. 2010;51:260-5. doi: 10.4111/kju.2010.51.4.260.
8. Rushton HG, Majd M, Chandra R, Yim D. Evaluation of 99mtechnetium-dimercapto-succinic acid renal scans in experimental acute pyelonephritis in piglets. *J Urol*. 1988;140: 1169-74.
9. Wongbencharat K, Tongpenyai Y, Na-Rungsri K. Renal ultrasound and DMSA scan screening for high grade vesicoureteral reflux. *Pediatr Int*. 2016;58:214-8. doi: 10.1111/ped.12803.
10. Hansson S, Martinell J, Stokland E, Jodal U. The natural history of bacteriuria in childhood. *Infect Dis Clin North Am*. 1997;11:499-512.
11. Hoberman A, Wald ER, Reynolds EA, Penchansky L, Charron M. Pyuria and bacteriuria in urine specimens obtained by catheter from young children with fever. *J Pediatr*. 1994;124:513-9.
12. Hoberman A, Charron M, Hickey RW, Baskin M, Kearney DH, Wald ER. Imaging studies after a first febrile urinary tract infection in young children. *N Engl J Med*. 2003;348: 195-202. doi: 10.1056/NEJMoa021698.
13. Cherry J HG, Kaplan S, Hotez PJ. *Textbook of pediatric infectious diseases*. 7th Ed. Elsevier; 2014.
14. Tseng MH, Lin WJ, Lo WT, Wang SR, Chu ML, Wang CC. Does a normal DMSA obviate the performance of voiding cystourethrography in evaluation of young children after their first urinary tract infection? *J Pediatr*. 2007;150:96-9. doi: 10.1016/j.jpeds.2006.09.028.
15. Preda I, Jodal U, Sixt R, Stokland E, Hansson S. Normal dimercaptosuccinic acid scintigraphy makes voiding cystourethrography unnecessary after urinary tract infection. *J Pediatr* 2007;151:581-4. doi: 10.1016/j.jpeds.2007.05.008.
16. Huicho L, Campos-Sanchez M, Alamo C. Metaanalysis of urine screening tests for determining the risk of urinary tract infection in children. *Pediatr Infect Dis J*. 2002;21:1-11.
17. Avner ED, Harmon WE, Niaudet P, Yoshikawa N, Emma F, Goldstein SL. *Pediatric Nephrology*. 7th ed. New York: Springer; 2016. p. 1696-1710.
18. Patel K, Charron M, Hoberman A, Brown ML, Rogers KD. Intra- and interobserver variability in interpretation of DMSA scans using a set of standardized criteria. *Pediatr Radiol*. 1993;23:506-9.
19. Coulthard MG, Lambert HJ, Keir MJ. Occurrence of renal scars in children after their first referral for urinary tract infection. *BMJ*. 1997;315:918-9. doi: 10.1136/bmj.315.7113.918.
20. Sharifian M, Dalirani R, Maham S, Akhavan Sepahi M, Karimi A, Ghaffari Shad M, Dadkhah Chymeh M, et al. Spontaneous resolution of vesicoureteral reflux (VUR) in Iranian children: a single center experience in 533 cases. *Nephro-Urol Mon*. 2011;3:191-195
21. Hellerstein S. Acute urinary tract infection--evaluation and treatment. *Curr Opin Pediatr*. 2006;18:134-8. doi: 10.1097/01.mop.0000193271.09001.a3.

22. Wald ER. Vesicoureteral reflux: the role of antibiotic prophylaxis. *Pediatrics*. 2006;117:919-22. doi: 10.1542/peds.2005-2139.
23. Nickavar A, Sotoudeh K. Treatment and prophylaxis in pediatric urinary tract infection. *Int J Prev Med*. 2011;2:4-9.
24. Roupakias S, Sinopidis X, Karatza A, Varvarigou A. Predictive risk factors in childhood urinary tract infection, vesicoureteral reflux, and renal scarring management. *Clin Pediatr (Phila)*. 2014;53:1119-33.
25. Friedman S, Reif S, Assia A, Mishaal R, Levy I. Clinical and laboratory characteristics of non-E. Coli urinary tract infections. *Arch Dis Child*. 2006;91:845-6. doi: 10.1136/adc.2005.080721.
26. Abdelhalim A, Khoury AE. Critical appraisal of the top-down approach for vesicoureteral reflux. *Investig Clin Urol*. 2017;58:S14-22. doi: 10.4111/icu.2017.58.S1.S14.
27. Shaikh N, Spingarn RB, Hum SW. Dimercaptosuccinic acid scan or ultrasound in screening for vesicoureteral reflux among children with urinary tract infections. *Cochrane Database Syst Rev*. 2016;2016:CD010657. doi: 10.1002/14651858.CD010657.pub2.
28. Printza N, Papachristou F, Piretzi K, Goga C, Arsos G. Neither clinical nor biological data can predict renal involvement in infants with febrile urinary tract infection. *Pediatrics*. 2008;121:S143.
29. Jaksic E, Bogdanovic R, Artiko V, Saranovic DS, Petrasinovic Z, Petrovic M, et al. Diagnostic role of initial renal cortical scintigraphy in children with the first episode of acute pyelonephritis. *Ann Nucl Med*. 2011;25:37-43. doi: 10.1007/s12149-010-0431-5.
30. Nikibakhsh AA, Yekta Z, Mahmoodzadeh H, Karamiyar M, Fazel M. Technetium Tc 99m dimercaptosuccinic acid renal scintigraphy in diagnosis of urinary tract infections in children with negative culture. *Urol J*. 2006;3:139-43.
31. Franz M, Horl WH. Common errors in diagnosis and management of urinary tract infection. I: pathophysiology and diagnostic techniques. *Nephrol Dial Transplant*. 1999;14:2746-53. doi: 10.1093/ndt/14.11.2746.
32. Moorthy I, Wheat D, Gordon I. Ultrasonography in the evaluation of renal scarring using DMSA scan as the gold standard. *Pediatr Nephrol*. 2004;19:153-6. doi: 10.1007/s00467-003-1363-2.
33. Bhatnagar V, Mitra DK, Agarwala S, Kumar R, Patel C, Malhotra AK, et al. The role of DMSA scans in evaluation of the correlation between urinary tract infection, vesicoureteric reflux, and renal scarring. *Pediatr Surg Int*. 2002;18:128-34. doi: 10.1007/s003830100680.
34. Sorkhi H, Nooreddini H.G, Amiri M, Osia S, Farhadi-Niakee S. Prediction of vesicoureteral reflux in children with first urinary tract infection by dimercaptosuccinic acid and ultrasonography. *Iran J Pediatr*. 2012;22:57-62.

Copyright © 2019 The Author(s); Published by Society of Diabetic Nephropathy Prevention. This is an open-access article distributed under the terms of the Creative Commons Attribution License (<http://creativecommons.org/licenses/by/4.0>), which permits unrestricted use, distribution, and reproduction in any medium, provided the original work is properly cited.